SKELETAL SYSTEM

- The word skeleton comes from the Greek word skeleton meaning “dried up”.
- It is strong yet light adapted for its function of body protection and motion.
- The skeletal system includes bones, joints, cartilages and ligaments.
- The joint give the body flexibility and allow movements to occur.
- But from structural point of view, the human skeletal system consists of two main types of supportive connective tissue:
    1. Bone
    2. Cartilage.

Functions of the skeletal system:

1**. Support:** It forms the internal framework that supports and anchors all soft organs.

2. **Protection:** Bones protect soft body organs.

3. **Movement**: Skeletal muscles attached to the skeletal system use the bone to levers to move the body and its part.

4. **Storage:** Fat is stored in the internal cavities of bones.

Bone it self-serves as a storehouse of minerals. The most important being calcium and phosphors.

5. **Blood cell formation:** It occurs within the marrow cavities of certain bones.

BONE:

- Bone (osseous) is specialized connective tissue that has the strength of cast iron and lightness of pinewood.
- Living bone is not dry, brittle or dead.
- It is a moist changing, productive tissue that is continually resorbed, reformed and remodeled.

Types of bone:

1. **Long bone**: are called long as its length is greater than its width.
    - The most obvious long bones are in the arm and leg. They act as levers that pulled by contraction of muscles.
2. **Short bones:** are about equal in length, width and thickness, which are shaped with regular orientation.
    - They occur in the wrist and ankle.

3. **Flat bones** are thin or curved more often they are flat.
    - This includes ribs, scapulae, sternum and bone of cranium. Irregular bones, they do not fit neatly into any other category. Examples are the vertebral, facial, and hipbone.
4. **Sesamoid bones** are small bones embedded within certain tendons, the fibrous cord that connects muscle to bones.
    - Typical sesamoid bones are patella and pisiform carpal bone, which are in the tendon of quadriceps femuris and flexor carp ulnaris muscle respectively.
5. **Accessory bones** are most commonly found in the feet.
    - They usually occur in the developing bone and do not fuse completely.
    - They look like extra bones or broken on X-ray.
    - Sutural (wormian) bones are examples of accessory bones.

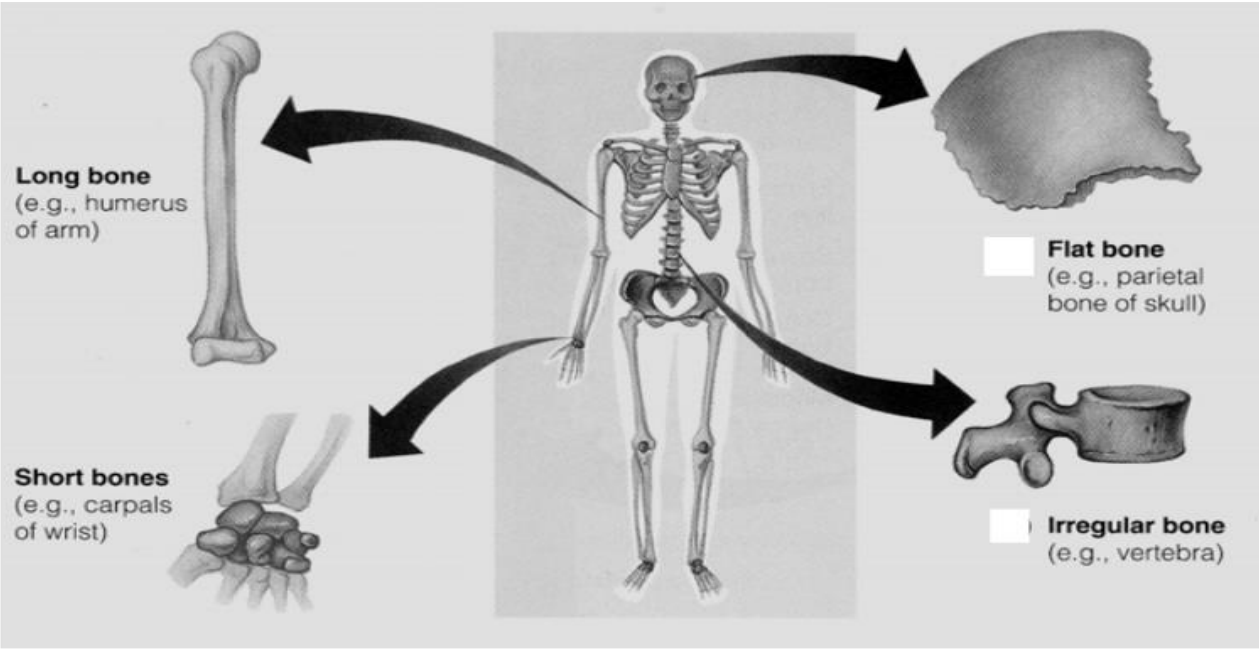

Structure of Bone Tissue

- There are two types of bone tissue: compact and spongy.
- The names imply that the two types differ in density, or how tightly the tissue is packed together. There are three types of cells that contribute to bone homeostasis.
- Osteoblasts are bone-forming cell, osteoclasts resorb or break down bone, and osteocytes are mature bone cells.
- An equilibrium between osteoblasts and osteoclasts maintains bone tissue.

Compact Bone:

- Compact bone consists of closely packed Osteons or Haversian systems.
- The osteon consists of a central canal called the Osteonic (haversian) canal, which is surrounded by concentric rings (lamellae) of matrix.
- Between the rings of matrix, the bone cells (osteocytes) are located in spaces called lacunae. Small channels (Canaliculi) radiate from the lacunae to the osteonic (Haversian) canal to provide passageways through the hard matrix.
- In compact bone, the haversian systems are packed tightly together to form what appears to be a solid mass.
- The osteonic canals contain blood vessels that are parallel to the long axis of the bone.
- These blood vessels interconnect, by way of perforating canals, with vessels on the surface of the bone.

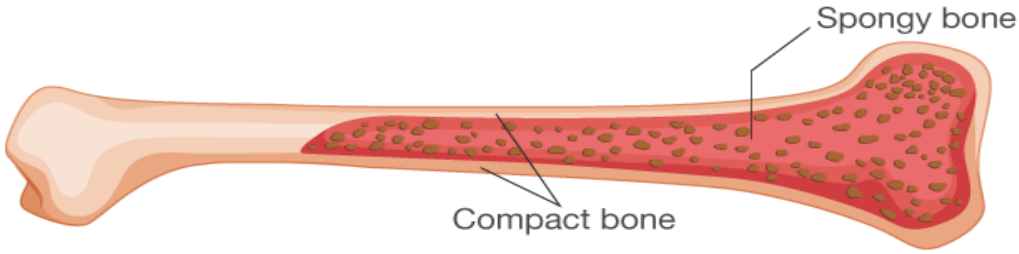

SPONGY BONE

- Spongy bone is also called cancellous or trabecular bone. It is found in the long bones and it is surrounded by compact bone.

COMPACT BONE

- Compact bone, also called cortical bone, surrounds spongy bone. They are heavy, tough and compact in nature

Spongy (Cancellous) Bone:

- Spongy (Cancellous) bone is lighter and less dense than compact bone.
- Spongy bone consists of plates (trabeculae) and bars of bone adjacent to small, irregular cavities that contain red bone marrow.
- The canaliculi connect to the adjacent cavities, instead of a central haversian canal, to receive their blood supply.

- It may appear that the trabeculae are arranged in a haphazard manner, but they are organized to provide maximum strength similar to braces that are used to support a building.
- The trabeculae of spongy bone follow the lines of stress and can realign if the direction of stress changes.

Illustration of compact and Spongy (cancellous) bone:

Feature	Compact Bone Tissue	Spongy Bone Tissue
Location	Outer layer of bones	Interior of bones
Structure	Densely packed osteons	Network of trabeculae
Appearance	Solid and dense	Honeycomb-like or spongy
Function	Provides strength and support	Supports metabolic needs and bone marrow production
Blood Supply	Central canals	Spaces between trabeculae
Density	Higher density	Lower density
Location in Bones	Diaphysis (shaft) and outer layer	Epiphysis (ends) and interior of flat/irregular bones

Classification of Bones:

- Illustration mapping the different components of a long bone:
- The bones of the body come in a variety of sizes and shapes.

The four principal types of bones are

1. Long
2. Short
3. Flat and
4. Irregular.

1. Long Bones

- Bones that are longer than they are wide are called long bones.
- They consist of a long shaft with two bulky ends or extremities.

- They are primarily compact bone but may have a large amount of spongy bone at the ends or extremities.
- Long bones include bones of the thigh, leg, arm, and forearm.

2. Short Bones

- Short bones are roughly cube shaped with vertical and horizontal dimensions approximately equal.
- They consist primarily of spongy bone, which is covered by a thin layer of compact bone.
- Short bones include the bones of the wrist and ankle.

3. Flat Bones

- Flat bones are thin, flattened, and usually curved.
- Most of the bones of the cranium are flat bones.

4. Irregular Bones

- Bones that are not in any of the above three categories are classified as irregular bones.
- They are primarily spongy bone that is covered with a thin layer of compact bone.
- The vertebrae and some of the bones in the skull are irregular bones.

- All bones have surface markings and characteristics that make a specific bone unique.
- There are holes, depressions, smooth facets, lines, projections and other markings.
- These usually represent passageways for vessels and nerves, points of articulation with other bones or points of attachment for tendons and ligaments.

Divisions of the Skeleton:

The adult human skeleton usually consists of 206 named bones.

These bones can be grouped in two divisions:

1. **Axial skeleton**
    - The 80 bones of the axial skeleton form the vertical axis of the body.
    - They include the bones of the head, vertebral column, ribs and breastbone or sternum.

2. Appendicular skeleton.

- The appendicular skeleton consists of 126 bones and includes the free appendages and their attachments to the axial skeleton.
- The free appendages are the upper and lower extremities, or limbs, and their attachments which are called girdles.

The named bones of the body are listed below by category.

Axial Skeleton (80 bones)

Skull: Bony structure of Head is called Skull (Highly organized and complex structure)

Functions of Skull:

- Skull protects and supports sensitive organs of the body like brain, eyes & ears.
- Movements in the head are due to cranial bones, which provides larger surface area for attachment of muscles.
- Cranial bones accommodate and stabilize the position of brain, cranial nerves and vessels.
- Facial bones form the framework of the face.
- Skull has various cavities which play an important role in communication of organs with environment
- The mandible and maxillae contain alveolar ridge in which teeth are present.
- These serve as supportive systems for entry into digestive and respiratory tracts.

Skull Bones (28)

Cranial Bones

Parietal (2)

Temporal (2)

Frontal (1)

Occipital (1)

Ethmoid (1)

Sphenoid (1)

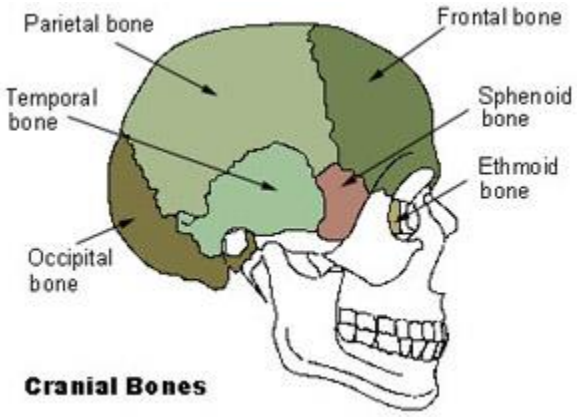

Facial Bones

Maxilla (2)

Zygomatic (2)

Mandible (1)

Nasal (2)

Platine (2)

Inferior nasal concha (2)

Lacrimal (2)-forming part of eye socket

Vomer (1)

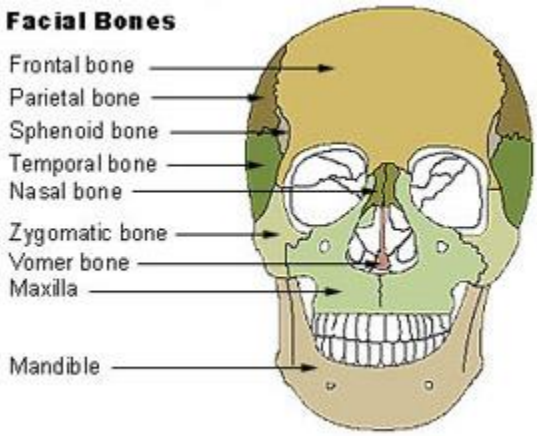

Auditory Ossicles

Malleus (2)

Incus (2)

Stapes (2)

- These are 3 small bones in middle ear that transmits vibrations

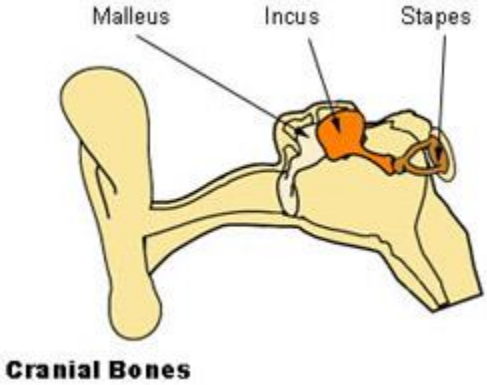

Vertebral Column:

- It is composed of bones and connective tissue.
- It is a flexible curved structure that provides axial support to the body.
- In this, the bones are called vertebrae.
- Vertebral column is formed by 26 irregular bones, which are connected and supported by ligaments.

Functions:

- Supports the head
- Helps to maintain balance in upright position

- Enclose and protects spinal cord
- Permits movement
- Absorbs shock during walking
- Serves as a point of attachment for the ribs, pelvic girdle and muscles of back & upper limbs.

<u>Vertebral Column</u> (Trunk bones)-26

1. **Cervical vertebrae (7):** Movable
- 7 vertebrae which are present in neck region
2. **Thoracic vertebrae (12):** Movable
- 12 vertebrae present in posterior region of thoracic cavity area
3. **Lumbar vertebrae (5):** Movable
- 5 vertebrae which supports the lower back
4. **Sacrum (1):** Immovable
- 5 sacral vertebrae fuse with one another to form a single region known as sacrum
5. **Coccyx (1):**
- 4 coccygeal vertebrae join to form a single structure

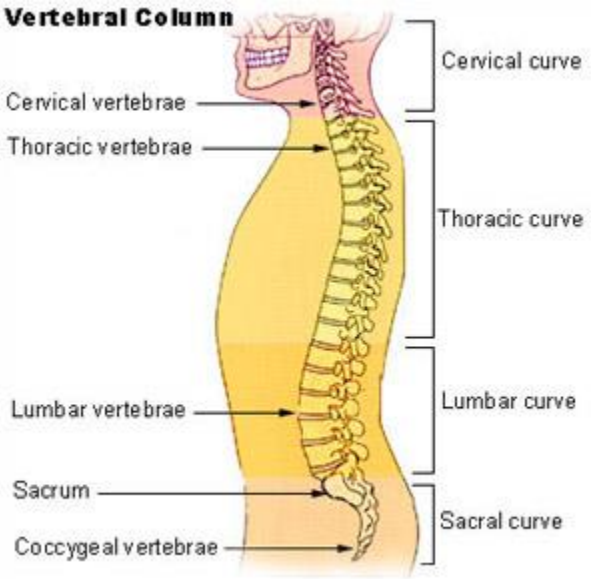

<u>Thorax / Rib cage / Thoracic cage:</u>

- Sternum, ribs and coastal cartilages of ribs & bodies of thoracic vertebrae makes a cone shaped cage like structure known as thoracic cage.
- Thoracic vertebrae serves as protective cover for organs like heart and lungs.
- They also support bones of shoulder girdle and upper extremities.

<u>Sternum:</u>

- Also known as breast bone
- Long flat bone located in the central part of chest
- Connects to ribs via coastal cartilage and forms the front of rib cage
- Helps to protect heart, lungs and major blood vessels from injury
- One of the longest and largest flat bones of our body
- It is divided into 3 regions.

i. Manubrium: Quadrangular shaped broader part that joins with the body of sternum, clavicles and cartilages of 1st pair of ribs
ii. Body/Gladiolus: Longest sternal part
iii. Xiphoid Process: Inferior end of sternum

Ribs:

A. True Ribs:

- 1-7 pairs in rib bones
- Also called Vertebro-Sternal ribs
- Attached to sternum & vertebrae form front & back end
- Forms upper part of rib cage
- Vertebrae are called Thoracic vertebrae

B. False Ribs:

- 8,9,10th pairs of rib-bones
- Also called Vertebra-Chondral ribs
- False ribs are connected to sternum through the 7th rib bones only
- Not joined directly to sternum like true ribs.

C. Floating ribs:

- Located in 11&12th pairs of rib bones
- Last 2 pairs of rib bones of rib cage
- Attached to one end of vertebrae of spinal cord. Other end is free.
- Weak attachment with vertebrae and zero attachment with sternum make it injury prone
- Hence floating ribs are fragile
- Attached to vertebral column at one point.

Thoracic Cage

Sternum (1)

Ribs (24)

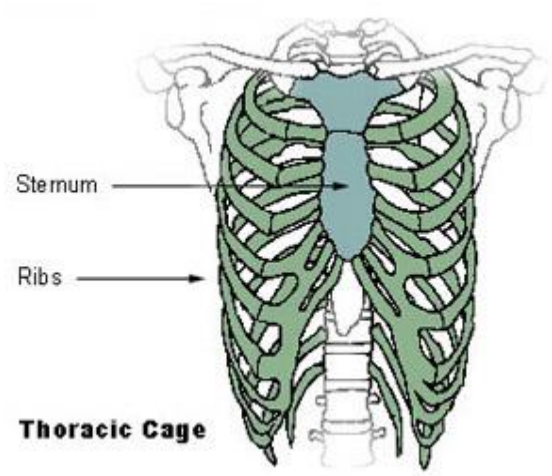

Hyoid bone:

- It is a horse-shoe shaped / u-shaped bone between larynx and mandible.
- It is a unique component of axial skeleton that do not join with any other bone.
- Through temporal bone, hyoid bone is suspended by means of ligament.
- Hyoid bone serves as point of attachment for tongue, neck and pharynx muscles.
- It also assists in keeping larynx open.

Appendicular Skeleton (126 bones):

- Consists of Upper limbs, Shoulder girdle, lower limbs & pelvic girdle.

A. Upper Limbs (Bones of Arm):

- Includes Arms, fore arms, wrists and hands

I. Humerus:

- Bone of Upper arm
- The Head site is within the Glenoid cavity of the scapula forming the shoulder joint
- Distally, at the elbow with 2 bones- Ulna & Radius.

II. Ulna & Radius:

- The Ulna is located on the medial aspect of fore arm, (the little finger side)
- Longer than radius
- The radius is smaller bone of arm located on lateral aspect of fore arm (the thumb side)
- Radius is narrow at proximal end and wider at distal end
- Ulna & Radius articulate with humerus at elbow joint
- Distal end of radius articulates with three bones of wrist – Lunate, Scaphoid & Triquetrum

III. Carpals, Metacarpals & Phalanges:

- The Carpus (wrist) is the proximal region of the hand
- Consists of 8 small bones (carpals) joined to each other by ligaments
- Scaphoid, Lunate, Triquetrum, Pisiform, Trapezium, Trapezoid, Capitate and Hamate
- Metacarpals or palmis intermediateregion of hand, having 5 bones called Metacarpals
- Each metacarpal bone consists of a proximal base, an intermediate shaftand a distal head (1 to 5 starting from thumb)
- Phalanges or bones of fingers or bones of digits make up distal part of hand
- There are 14 phalanges in the 5 digits of each hand, Digits are numbered 1 to 5 beginning with thumb.
- A single bone of digit is called Phalanx.
- Starting from thumb, other four digits are called Index finger, Middle finger, Ring finger and little finger.

- First row phalanges- Proximal row
- Second row phalanges- Middle row (excludes thumb)
- Third row- Distal row

Upper Extremity

- Humerus (2)
- Radius (2)
- Ulna (2)
- Carpals (16)
- Metacarpals (10)
- Phalanges (28)

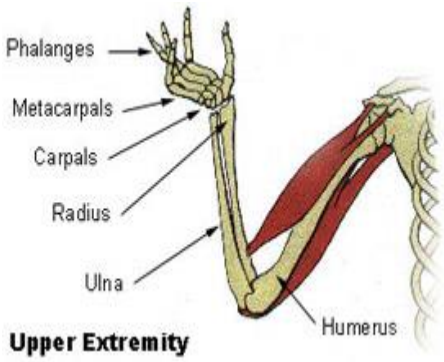

B. Pectoral (Shoulder) Girdle:

- The Human body has 2 pectoral or shoulder girdles attached to bones of upper limbs to axial skeleton
- Each pectoral girdle consists of Clavicle and Scapula

IV. Clavicle or Collar Bone:

- S-shaped
- It is rougher and more curved in males
- The medial end is rounded and articulates with manubriumof sternum to form Sterno-clavicular Joint.
- The broad, flat and lateral end articulates with the Acromion of Scapula to form Acromio-clavicular joint.
- Conoid ligaments attach the Clavicle & Scapula

V. Scapula (Shoulder Bone):

- It is a large, triangular, flat bone situated in superior part of posterior thorax between level of 2nd and 7th ribs.
- A prominent ridge called spine runs diagonally across posterior surface of scapula.
- Lateral end of spine projects a flattened expanded process called Acromion
- Thin edge of scapula closer to vertebral column is called medial (Vertebral) border.
- Thick edge closer to arm is called lateral (Axillary) border.

Pectoral girdles

- Clavicle (2)
- Scapula (2)

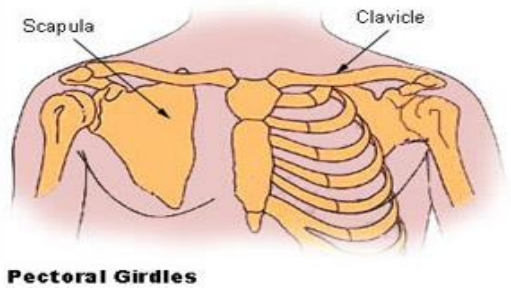

C. Pelvic Girdle (HIP):

- The pelvic(hip) girdle consists of 2 hip bones called Coxal or pelvic bones or Coxa
- The hip bones unite anteriorly at a joint called pubic Symphysis.
- They unite posteriorly with sacrum at sacroiliac joints.
- Functionally the bone at pelvis provides a strong and stable support for the vertebral column, pelvic and lower abdominal organs.
- The pelvic girdle, also connects bones of lower limbs to axial skeleton
- The structure of pectoral (shoulder) girdle offers more mobility than strength
- Pelvic girdle offers more strength than mobility
- Although the hip bones function as single bones but anatomists commonly discuss each hip bone as 3 separate bones

i. Ilium:

- It is the largest bone of hipbone composed of superior and inferior body
- The body helps forming Acetabulum socket for the head of femur

ii. Ischium:

- Inferior and posterior portion of hip bone
- Comprised of superior body and inferior ramus.

iii. Pubis:

- Anterior and inferior part of hip bone
- A superior ramus, inferior ramus and a body between rami comprise the pubis.

Pelvic Girdle:

- Coxal, innominate, or hip bones (2)

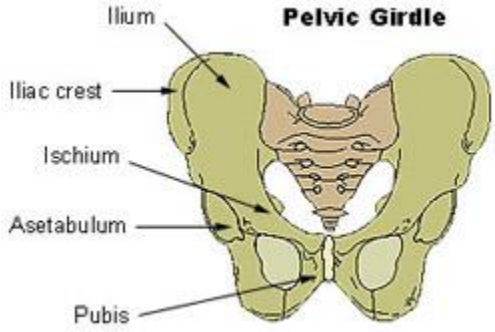

D. Lower Limbs:

- Each lower limb has 30 bones
- Femur in thigh, patella in knee cap, tibia and fibula in leg, 7 tarsals (ankle), 5 meta tarsals and 14 phalanges in foot (bones of digits)

i. Femur (Thigh bone):

- Longest, heaviest, strongest bone in the body
- Its proximal articulates with acetabulum of the hip bone (proximal end has rounded head)
- Distal end articulates with the tibia and patella
- Body (shaft) of femur angles medially, so that the knee joints are closer to midline.

- Angle is greater in female because female pelvis is broader.
- Extended distal end of femur include medial condyle and lateral condyle.

ii. Patella:

- Small triangular bone located to Anterior joint
- The broad proximal end of the sesamoid bone is called Base
- The pointed distal end is called Apex.
- The posterior surface contains 2 articular facets (one for medial condyle and one for lateral condyle of femur)

iii. Tibia and Fibula:

- Larger, medial, weight bearing bone of the leg
- Tibia articulates at its proximal end with femur and fibula; and its distal end with fibula and talus bone of ankle.
- Tibia & Fibula as ulna and radius connected by an Interosseous membrane.
- The proximal end of tibia is expanded into : a. lateral condyle b. medial condyle
- The fibula is parallel and lateral to tibula
- The head of fibula, the proximal end articulates with inferior surface of lateral condyle of tibia form tibiofibular joint.
- The distal end articulates with talus of the ankle.

iv. Tarsals, Metatarsals and Phalanges:

- The tarsus (Ankle) is proximal region of foot and consists of 7 tarsal bones
- Talus and Calcaneus (largest and strong tarsal bones), Navicular, Cuboid, 3 Cuneiform bones
- Joints between tarsal bones are called Intertarsal joints
- The talus bone is the only bone of foot That articulates with fibula and tibia
- The metatarsus intermediate region of the foot consists of Metatarsal bones (from medial to lateral)
- Each metatarsal consists of: a. a proximal base, b. an intermediate shaft, c. A distal head
- Metatarsals articulate proximally with 1st, 2nd and 3rd cuneiform and cuboid bones (forms tarso-metatarsal joints)
- Distally they articulate with proximal row of phalanges to form Metatarso-phalangeal Joints.
- The phalanges comprise distal component of foot same as hand in both number (14) and arrangement.

- Joints between phalanges of foot are called Inter-phalangeal Joints.

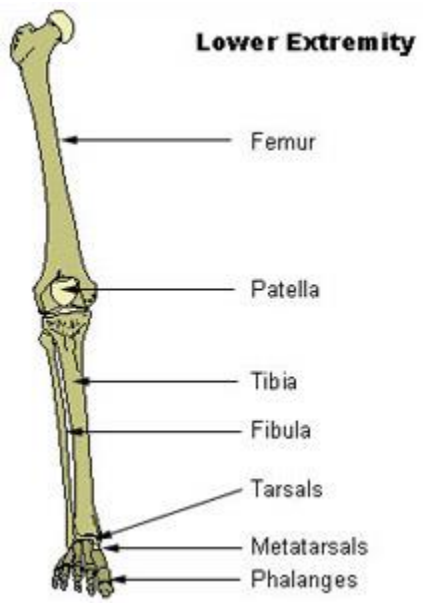

Lower Extremity:
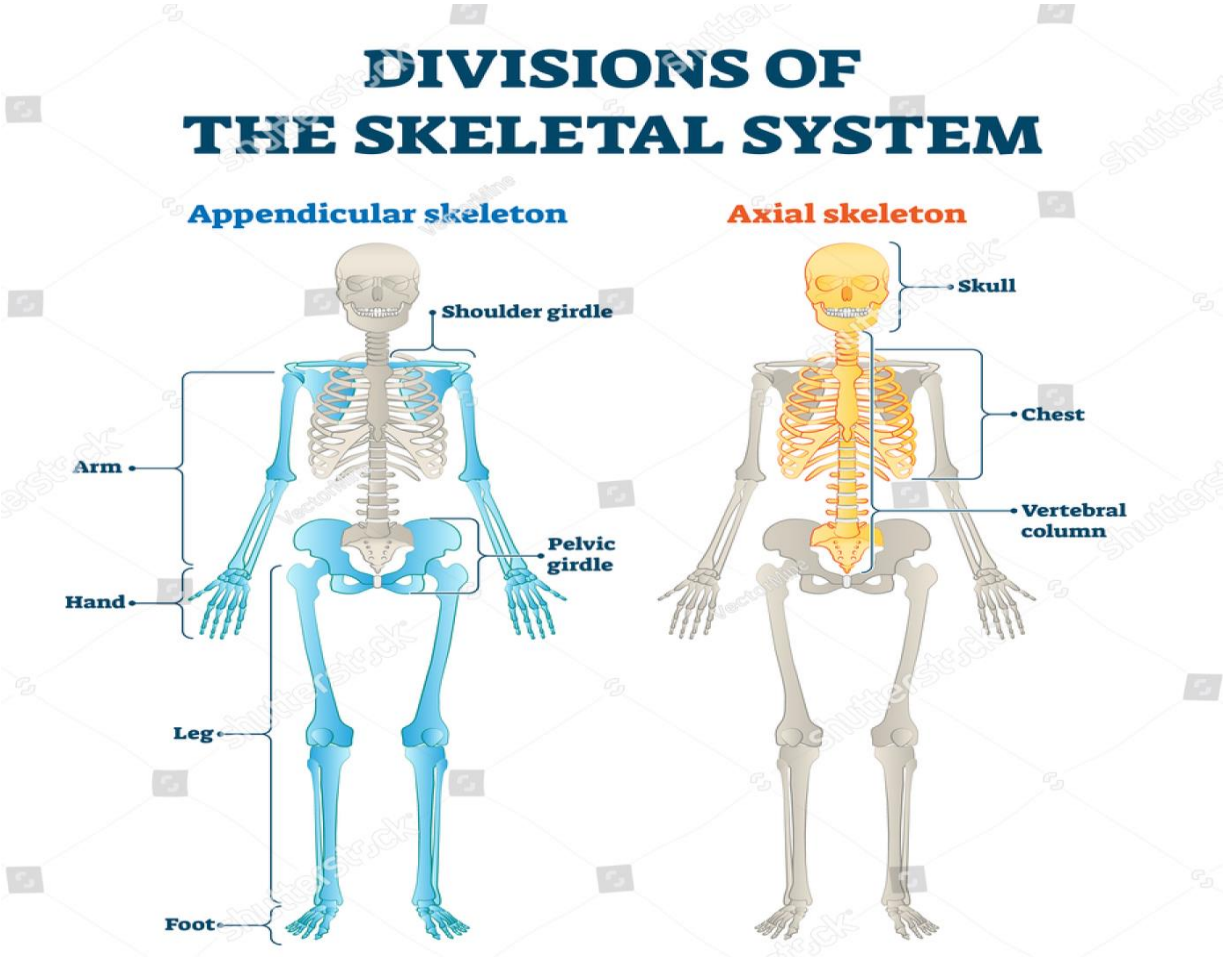
- Femur (2)
- Tibia (2)
- Fibula (2)
- Patella (2)
- Tarsals (14)
- Metatarsals (10)
- Phalanges (28)